



RESEARCH ARTICLE

Open Access

## Nipple Repair and Pain Reduction in Breastfeeding Women after Low-Level Laser Therapy Irradiation: A Pilot Study

Sabrina Peviani<sup>1</sup>, Antonio Eduardo de Aquino Junior<sup>1\*</sup>, Fernanda Mansano Carbinatto<sup>1</sup>, Claudia Pignatti Frederice<sup>2</sup>, Iago Silva E Carvalho<sup>1,3</sup>, Daniel Jose Chianfrone<sup>1</sup> and Vanderlei Salvador Bagnato<sup>1,3</sup>

<sup>1</sup>Physics Institute of São Carlos, University of São Paulo, São Carlos, São Paulo, Brazil.

<sup>2</sup>Pelvicare Clinic, Campinas, São Paulo, Brazil.

<sup>3</sup>Department of Biomedical Engineering, Texas A&M University, Texas, United States of America.

### ABSTRACT

**Purpose:** Nipple pain and trauma are common problem and a huge barrier to continued breastfeeding due to the pain and discomfort. Photobiomodulation therapy (PBMT) is a treatment option for nipple pain and trauma. This study evaluated the effect of adapter coupled in low-level laser therapy equipment in modulating tissue repair and pain among women with nipple trauma.

**Methods:** Two groups were evaluated: Standard treatment Group (StGroup;n=8): lactants received orientation about breastfeeding techniques; and Laser Group (LGroup; n=8): lactants received standard treatment plus irradiation laser (660nm; irradiance of 12 mw/cm<sup>2</sup>, 40s, total energy delivered of 4,62J). Nipple lesion area was measurement by photographic image and subsequent software analysis before and after 24 hours after laser application. Pain intensity was assessed by Visual Analogue Scale (VAS).

**Results:** There was a reduction in nipple lesion areas as in StGroup (p<0.002) as in LGroup (p<0.0005) and pain intensity in StGroup (p<0.001) and in LGroup (p<0.0001), after one and two sessions (p<0.0001).

**Conclusion:** The adapter was efficient to improve the nipple repair, as well as reduced the pain intensity in breastfeeding women. This new adapter has allowed to expand the irradiated tissue area (nipple and areolar region), facilitating the laser using method, avoiding the accumulation of red light in the melanin present in the nipples, reducing the chance of adverse effects and enabling the use of a higher dose of energy, necessary to promote pain reduction.

### ARTICLE HISTORY

Received 11 Apr 2025

Accepted 21 May 2025

Published 30 May 2025

### KEYWORDS

Breast Feeding, Low-Level Light Therapy, Nipple, Pain measurement, Photobiomodulation.

### Introduction

The importance of breastfeeding for infant nutrition is undoubted. It is widely recognized as gold standard [1] recommendation from the World Health Organization (WHO) that babies should be fed exclusively with breast milk in the first six months of life, without the introduction of other liquids or solid foods [2].

In addition, breastfeeding reduces the incidence of diseases and the mortality rate in the baby's first year of life [3,4]. Furthermore, breastfeeding plays a fundamental role in strengthening the emotional bond between mother and baby, also promoting the health mother like the return of uterine size, decreased postpartum bleeding, lactational amenorrhea, reduced postpartum depression and lower risks of breast and ovarian cancers, diabetes, osteoporosis [5,6].

Breastfeeding has also positive economic aspects. Compared to the use of artificial formulas, breastfeeding is considerably more economical, and avoid expenses related to diseases associated with artificial feeding [7]. However, the rate is still 45.7% (for children younger than 6 months) according to data from the Brazilian National Survey on Child Nutrition [8], which remains below the 70% recommended levels for WHO.

There are several challenges and complications that can impact the success of breastfeeding, resulting in early weaning. The lack of preventive orientations, incorrect positioning, inadequate attachment of the baby, the use of nipple shields, breast engorgement, and the frequency and duration of feedings, among other factors, can lead nipple trauma and pain [9,10].

Nipple trauma can be characterized by rupture of the cutaneous barrier in the nipple-areolar complex, which can

**Contact** Antonio Eduardo de Aquino Junior, Physics Institute of São Carlos, University of São Paulo, São Carlos, São Paulo, Brazil.

© 2025 The Authors. This is an open access article under the terms of the Creative Commons Attribution NonCommercial ShareAlike 4.0 (<https://creativecommons.org/licenses/by-nc-sa/4.0/>).

reach the epidermis and/or dermis, and involve different skin structures, commonly associated to local pain [11,12] limiting the continued breastfeeding. In the first 8 week of postpartum more than 79% of women reported pain during breastfeeding, and 58% of women reported nipple trauma [13].

Best practice recommendations for breastfeeding techniques in early stages are important to reduce nipple trauma [10,14,15]. One therapeutic possibility that has been studied for the treatment of nipple trauma is PBMT using non-ionizing light sources including lasers, LEDs in the visible band light and infrared spectrum [16] that acts on endogenous chromophores, modulating cellular functioning, activating cell signaling mechanisms that promotes proliferation, differentiation, vascularization and regulation of the inflammatory process, favoring tissue repair and pain relief [17]. It can be a promising option in the treatment of nipple trauma and pain [18,19].

The lack of scientific evidence for most treatments proposed to nipple trauma represents a significant challenge for healthcare professionals dealing with breastfeeding women who suffer from this type of injuries. For this reason, strategies and resources that can strengthen, facilitate, protect and support breastfeeding are of fundamental importance for improve breastfeeding duration and exclusivity rates. There are few studies addressing the effectiveness of low-level laser therapy in nipple trauma, but they use different dosage parameters, since there is no consensus on this and on the locations and points of application. Therefore, an adapter (coupled to already commercialized equipment Recover® - MMOptics, São Carlos/SP, Brazil) was developed, which allows the light to spread evenly, without requiring direct contact with the injured area.

The present study aims to evaluate the effect of adapter coupled in low-level laser therapy equipment in modulating tissue repair and pain among women with nipple trauma.

## Materials and Methods

### Study Design and Participants

This is a randomized clinical trial with a convenience sample, approved by the Research Ethics Committee of the Irmandade da Santa Casa de Misericórdia de São Carlos (CAAE: 73235423.9.0000.8148), Brazil, according to resolution 466/2012.

All women were clarified about entire studies before these women signed an informed consent term to participate in the study. From September 2023 to February 2024 at the Maternity Dona Francisca Cintra Silva da Santa Casa de São Carlos, Brazil we included postpartum women aged 18 years or older; diagnosed with nipple trauma (abrasion, crack, or fissure), and nipple pain with a minimum score of 3 on the visual analogue pain scale; no clinical signs of infection, being exclusively breastfed and with a newborn without oral, palatine or maxillofacial abnormalities. We excluded women who use photosensitizing medications, have mastitis, and those who use a breast pump or silicone nipple.

The randomization sequence list was generated by Excel

program. An equally simple randomization procedure was performed using computer-generated random numbers, with a 1:1 allocation ratio for two groups (Standard treatment Group - Control Group and Laser Group) and permuted block size of 10. Information on treatment allocation was concealed within sealed opaque envelopes, identified by number. The envelopes were opened only after participants signed the informed consent term.

### Treatment's Group

#### Standard Group (StGroup)

Volunteers received information about breast care and individualized assistance in breastfeeding for the researcher physiotherapist, considered as Standard treatment. The objective was to improve the nipple trauma. The oral and leaflet recommendations included:

- a) Baby alignment during breastfeeding: the baby must be close to the mother's body ("belly to belly"), with head and body aligned and with mouth at the level of the nipple, with the baby's head and buttocks supported.
- b) Adequate latching of the baby: It is very important to ensure that baby takes all or most part of the areola. One way to help is to touch the baby's lower lip with the nipple and wait until the baby has its mouth wide open. With the help of the hand in the shape of "C", make it like a "sandwich" and place the breast in the baby's mouth, bringing baby towards breast, helping to grasp as much of the areola as possible.
- c) Correct way to remove the baby from the breast: with the clean hands, place the little finger on the corner of the baby's mouth until he/she releases the "vacuum" and only then remove the baby.
- d) Relief milking to keep the areola soft and avoid breast engorgement.
- e) Recommendation not to use creams or other products on the nipples.
- f) Not using pacifiers, bottles or shells.

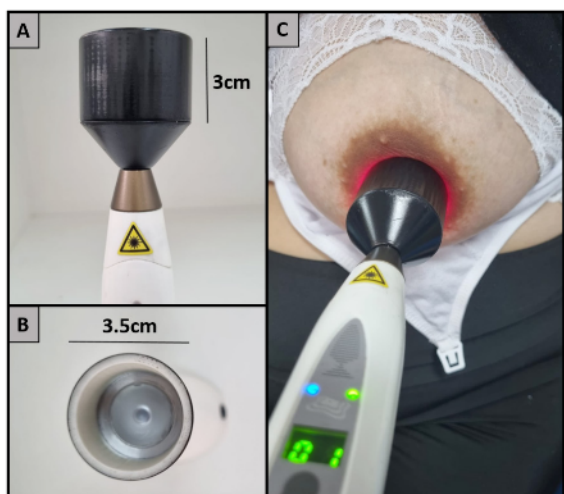
#### Laser Group (LGroup)

In this group, the volunteers received the standard treatment as described above and were submitted to low-level laser therapy. The irradiation source was an adaptation of Recover®, a clinical portable model developed by MMOptics Ltda certified by ANVISA (National Agency for Sanitary Surveillance) and consist in a diode laser that emit light in red (660 nm) or infrared (808 nm) wavelengths. In this study, the emission in 660 nm was fixed and the spot size of equipment (0,03 cm<sup>2</sup>) was changed with adapter to 9,62 cm<sup>2</sup> of irradiation area that was developed by the Laboratory of Technical Support by Physics Institute of São Carlos, University of São Paulo, São Carlos/SP, Brazil. The adapter has a special lens that corrects the divergence emitted by the laser, producing an almost collimated beam allowing uniform lighting and delivering uniform dose of light to the entire region. For the source, an irradiance of 12 mw/cm<sup>2</sup> and a total energy delivered of 4,62 J was chosen. To this, the 9,62 cm<sup>2</sup> spot was positioned fixed upside of the skin (Figure 1) by 40s. To monitor the power transmission of light by the source was used a LabMax PM300F-50 (Coherent, Inc., Santa Clara, CA, USA).

During the treatment, the patient and the physiotherapist wore

protective glasses with a specific filter for the wavelength used. effect of one session and two sessions of laser.

Figure 1 A, B: Characteristics of the adapter coupled to equipment



Recover®: a tubular structure of 3cm long and 3.5cm of diameter, with an internal collimating lens, allowing to expand the irradiated tissue area. Another advantage of this adapter was to irradiate the lesion area without direct contact. C: The format of the equipment and adapter allows application perpendicular to the skin, in a 90° position.

**Procedures**

After participants signed the informed consent term, demographic and obstetric data were collected by a questionnaire (age, gestational age, birth weight, type of delivery, number of days postpartum). After that the pain was assessed by Visual Analogue Scale (VAS) on a scale from 0 to 10 [20]. Women marked their pain intensity on a 10-cm line, with 0 (“no pain”) and 10 (“worst pain”), during breastfeeding in the breast with nipple trauma in both group (StGroup and LGroup) and immediately after irradiation in laser group (LGroup). The breasts were photographed before the intervention and 24 hours after the intervention.

**Assessment of Nipple Lesion Images**

A Samsung S21 cell phone camera was used to capture the images and subsequent analysis using the IMAGE J 1.54d software. The breasts were photographed before the intervention and 24 hours after the intervention. A ruler was used as a reference for image analysis, carried out in the frontal view, positioned close to the lesion, allowing the standardization of the scale in the measurements of the lesion area. All images were taken by the same evaluator, maintaining standardization and confidentiality with the patients.

**Outcomes**

Our primary outcome was to assess the impact of Laser in the nipple lesion area by photographic image and subsequent software analysis before and after 24 hours after laser application. In relation to nipple lesion area was presented the effect of only one session laser. Our secondary analysis was to evaluate the effects of St alone or combined with Laser (LGroup) in nipple pain assessed by VAS. Intensity pain was evaluated before and immediately after laser each application, as well as after 24h. In relation to pain intensity was presented both the

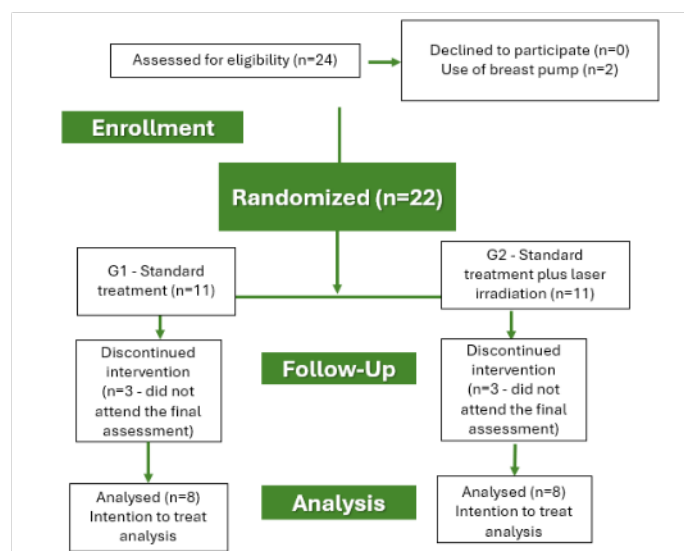
**Statistical Analysis**

Statistical analysis was performed using the GraphPad InStat 3.0 software for Windows. The Komogorov-Smirnov was used for normality of data distribution and equality of variances. In all statistical analyses, p values < 0.05 were considered as statistically significant. To compare measurements of nipple lesion areas and pain intensity, both within groups and between groups, the Student's t test was used.

**Results**

A total of 24 women were eligible, however 2 of them were using breast pump and were not included. Thus, 22 women were randomized to the G1 – Standard Group: StGroup (n = 11) and to the G2 – Standard Group plus Laser – LGroup (n = 11). In the StGroup and in the LGroup, 8 women completed the treatment and the final assessment. Three women in each group (n=6) did not complete the final assessment and were discontinued. The flowchart of participants is shown in figure 2.

Figure 2: Flowchart of the participants.



The average age of the participants was 22.8 years (+/- 4.1), primigravidae, babies with > 38 weeks of gestation; 11(68.75%) had a cesarean section, and 5 participants (31.25%) had a vaginal birth. Of the 16 volunteers, 14 (87.5%) reported to have difficulty performing adequate breastfeeding techniques during the hospitalization period. Table 1 shows data by group.

Table 1: Characteristics of participants by Group.

	Standard Group (StGroup; n=8)	Laser Group (LGroup; n=8)
Age (years)	22,5 (+/- 4,9)	23,7 (+- 5,4)
Type of delivery		
Vaginal	3 (37,5%)	2 (25%)
Cesarian	5 (62,5%)	6 (75%)
Difficulty with breastfeeding techniques	6 (75%)	8 (100%)

**Nipple Lesion Area**

Our results showed that the StGroup and LGroup improved the repair of breast lesions, as exhibit in Figure 3 (A, B, C, D).

Regarding the measurements of nipple lesion areas, in the StGroup there was a reduction in lesion area ( $p < 0.002$ ), being Day 1 ( $0.36 \pm 0.20 \text{ cm}^2$ ) x Day 2 ( $0.28 \pm 0.16 \text{ cm}^2$ ), also in LGroup ( $p < 0.0005$ ), with Day 1 ( $0.44 \pm 0.11 \text{ cm}^2$ ) x Day 2 ( $0.23 \pm 0.07 \text{ cm}^2$ ), suggesting that best practice recommendations for breastfeeding techniques are important and favors the improvement of injuries and laser irradiation promotes better healing of breast lesions after one session (Figure 3 E).

At lesion areas, considering the average percentage difference (equation1) between the initial state (Day 1) and the final state (Day 2), it was possible to observe a difference ( $p < 0.01$ ) between the StGroup ( $-25.8 \pm 9.7$ ) versus LGroup ( $-45.6 \pm 12.5$ ), suggesting that the combination of laser and standard treatment promotes even more positive effect on healing tissue (Figure 3F).

$$\Delta\% = \frac{\text{Final Value} - \text{Initial Value}}{\text{Initial Value}} \cdot 100 \quad (1)$$

**Pain Intensity**

Analyzing the pain intensity, assessed by VAS, a reduction was observed in StGroup Day 1 ( $4.5 \pm 1.20$ ) x Day 2 ( $3.1 \pm 0.8$ ) ( $p < 0.001$ ), also observed in LGroup, with Day 1 ( $7.2 \pm 2.1$ ) x Day 2 ( $4.7 \pm 1.7$ ) ( $p < 0.0001$ ), suggesting that the standard treatment and laser intervention were efficient in reducing pain (Figure 4A).

In the mean percentage, by equation 1, the difference between initial (Day 1) and final pain (Day 2), a difference ( $p < 0.01$ ) between the StGroup ( $-29.7 \pm 12.9$ ) versus LGroup ( $-54.9 \pm 20$ ), suggesting that the combination of laser + standard treatment are more efficiently compared to the intervention considered

standard (Figure 4B).

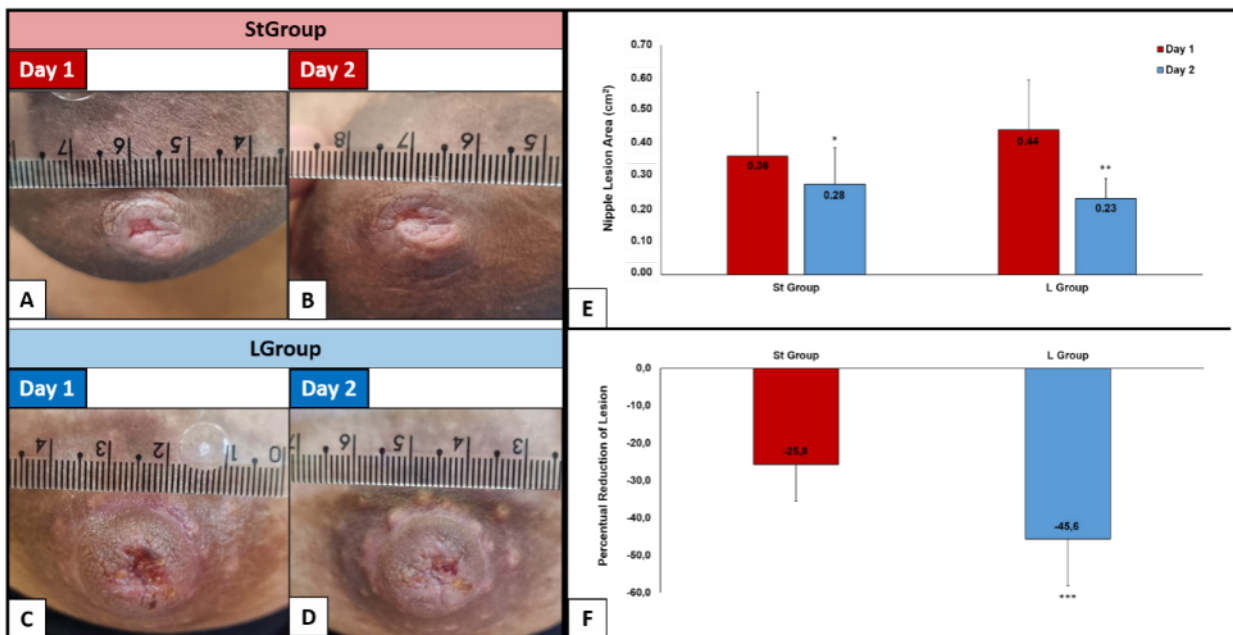
Figure 5 shows the comparison and evolution of the effect of low-level laser therapy after two sessions in relation to pain intensity. It is also possible to observe the immediate effect of the low-level laser before and after its application, in relation to each irradiation session. In the comparison of session 1, a reduction in pain intensity ( $p < 0.0001$ ) was observed, initial value at 7.3 and final value at 3.8. In comparison of session 2, there was a reduction in pain intensity ( $p < 0.0001$ ), with an initial value of 4.8 and a final value of 2.4.

**Discussion**

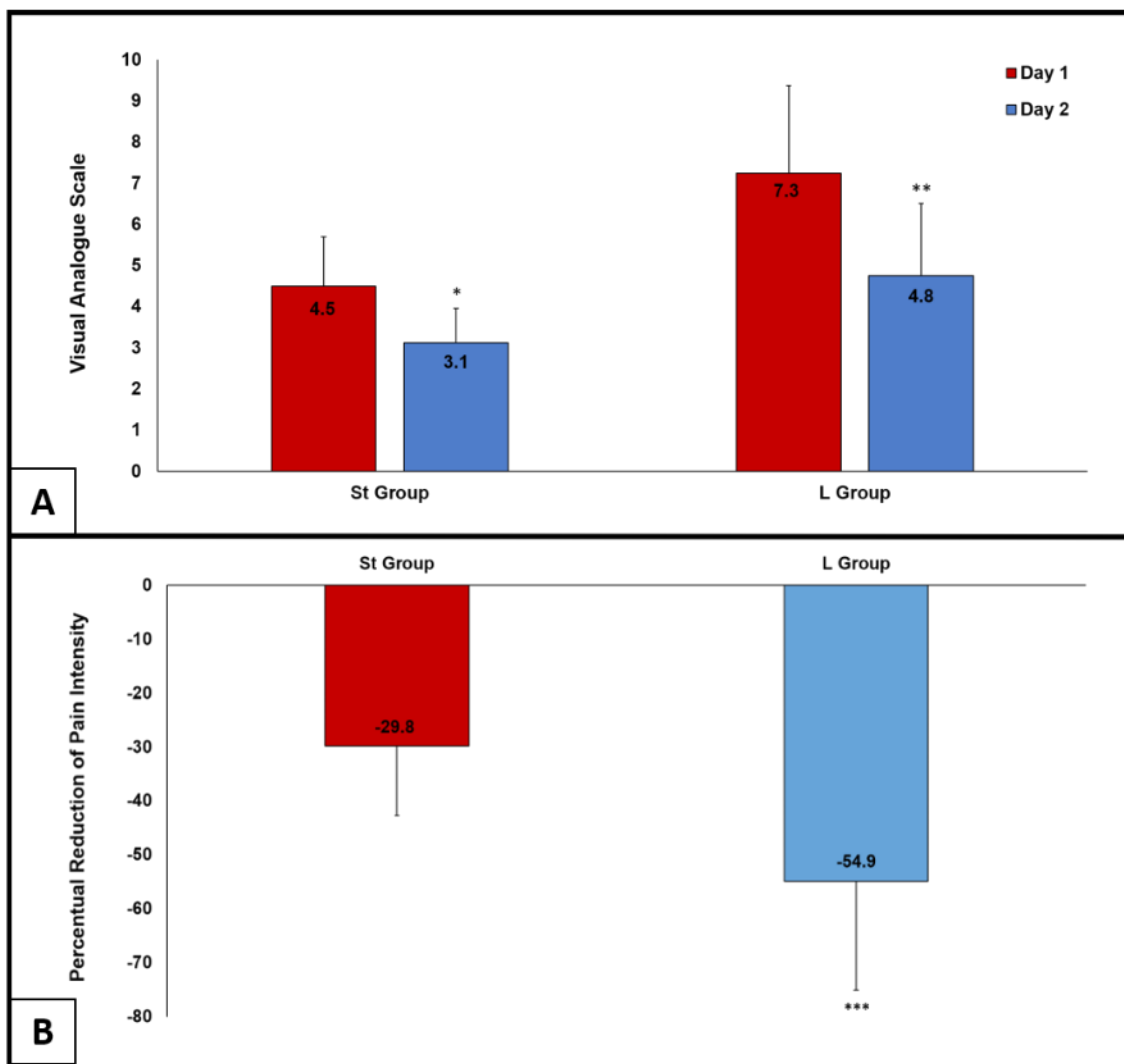
Nipple pain and trauma are common problem which are caused by pressure exerted on nipple and areola area and friction during the baby's sucking harming breastfeeding due to the pain and discomfort. In this context, our results showed that one session of low-level laser therapy irradiation associated to standard treatment were more efficient in improving nipple repair and pain reduction in lactating women.

PMBT has had been a promising option in treatment of nipple pain and trauma [18,19]. There is evidence that the effectiveness of treatment can vary significantly according to the energy density and power used. Apparently, there are upper and lower limits for both parameters within which low-intensity light therapy is effective [22]. The laser parameters used in this study have showed be efficient (red light with 660nm, continuous mode, a dose of 4.62J in 40 seconds) - in improving nipple repair and reducing pain. It is interesting to mention that no women described sensations such as tingling or stinging, as described in other studies [23].

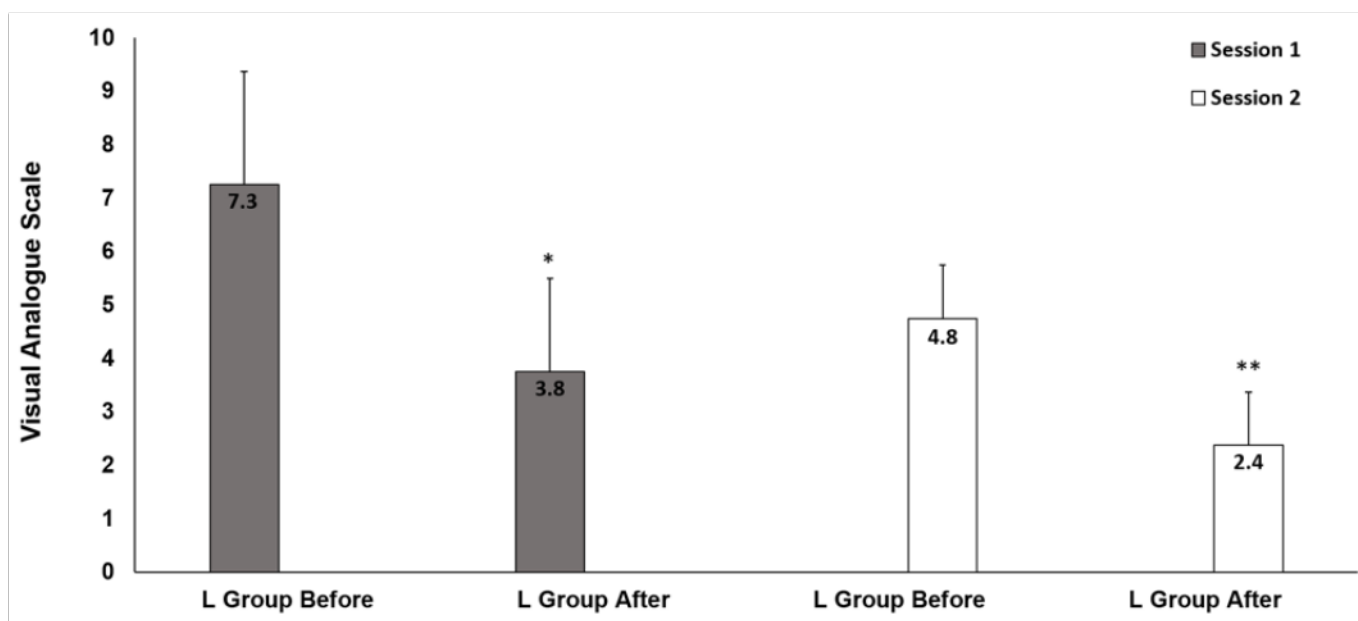
The basis of the effects of low intensity laser consists of the



**Figure 3:** Nipple Lesion Analysis: The breasts were photographed before (Day 1) and 24 hours after the intervention (Day 2). The images represent a nipple trauma of StGroup (A and B) and LGroup (C and D). Measurements of nipple lesion areas on Day 1 e Day 2 in StGroup and LGroup (E): there was a significant reduction in nipple lesion areas as in StGroup (\* $p < 0.002$ ) as in LGroup (\*\* $p < 0.0005$ ) comparing Day 1 x Day 2. It was observed a significant difference between groups (\*\* $p < 0.01$ ) on mean percentual reduction of lesion (F).



**Figure 4: Pain Intensity:** significant pain intensity reduction was observed in the StGroup (\* $p < 0.001$ ) and in LGroup (\*\* $p < 0.0001$ ) on Day 1 x Day 2 (A). It was observed a significant difference between groups (\*\* $p < 0.01$ ) on mean percentual reduction of Pain Intensity between StGroup and LGroup (B).



**Figure 5: Pain Intensity evaluated by Visual Analogue Scale comparing before and immediately after laser application:** A reduction in pain intensity was observed immediately after one session of laser (initial at 7.3 and final at 3.8; \* $p < 0.0001$ ) and after two sessions (initial value of 4.8 and a final value of 2.4; \*\* $p < 0.0001$ ).

irradiation of cells, using a specific wavelength which can activate cellular components promoting specific chemical reactions, which can alter the cellular metabolism [17,24]. It is light generating a chain photoresponse. There is evidence about the effect of the light on mitochondria, through the absorption of light by the chromophores cytochrome c oxidase, which promotes increase of electron transport, oxygen consumption, mitochondrial membrane potential, and consequently synthesis of ATP, in addition to regulate cell signaling, growth factor synthesis, gene expression, and inflammatory modulation [25,26].

The present results are in accordance to the evidences in the literature, which demonstrate that low level laser therapy accelerates wound healing, which beneficial effects such as increased blood flow, improved tissue oxygenation, reduced inflammation and pain [25,26]. Our results showed that a single laser session improved the repair of breast lesions, evaluated through the analysis of images of the injured areas, through a significant reduction in the measured areas. Also, the laser proved to be more efficient considering the average percentage difference between the initial state (Day 1) and the final state (Day 2), between the StGroup versus LGroup, suggesting that the combination of laser and standard treatment promotes even more positive effect on healing tissue.

Chaves (2012) also observed an improve in the healing of nipple trauma and pain in breastfeeding women (in a similar way of the present study), after using LED phototherapy performed twice a week for a period per 4 weeks (infrared light 860 nm; frequency of 100 Hz; average power of 50 mW; power density of 50 mW/cm<sup>2</sup>; total emission area of 1cm<sup>2</sup>; and dose of 4 J/cm<sup>2</sup>). It was showed that the nipple lesions in the experimental group healed faster than (4 sessions) did the lesions in the control group, completely healed only by the eighth session. In this same study, it was observed a reduction on pain intensity, measured by an 11-point pain intensity numerical rating scale (PI-NRS).

In regarding the nipple pain intensity, our study evaluated a reduction in pain in both the StGroup (a reduction of 1.4 cm in VAS, with initial pain in 4.5cm) and LGroup (a reduction of 2.5 cm in VAS, with initial pain in 7.3cm). It was possible to assess that the laser provided an even greater reduction in pain intensity when compared to standard treatment.

Other studies also described the degree of pain between 4 and 7 centimeters, and this intensity of pain affected women's mood, sleep and daily activities, negatively affecting their quality of life [19,27]. Therefore, our results are encouraging in terms of helping pain in lactating women.

Furthermore, it was possible to observe the immediate effect after applying the laser (both after one session and after two sessions). Clinically, it was possible to observe how this immediate effect on pain relief was positive for the breastfeeding women to have more confidence and less fear in continuing breastfeeding. The breastfeeding women in the control group also continued breastfeeding, but it was possible to observe that many of them felt afraid.

The analgesic effect observed by low level laser may be

attributed to the reduction of inflammatory response, including reduction of edema [28], and declining in nociceptor signal transduction [29-31].

Coca (2016) observed a decrease of pain in lactant women with nipple lesions after three irradiation sessions of laser, in three different points in contact to the injured nipple. The intervention group experienced a decrease of 2.0 centimeters in intensity of pain 24 hours after the first intervention and presented lower levels of pain compared with the control group, but with no significant differences between the groups. These authors used 660nm laser with 40 milliwatt power (spot size 4 square millimeters), energy density of 5 J/cm<sup>2</sup> in 5 seconds (0.2 Joules per point).

This was possibly due to the parameters chosen in which the energy dose placed in the tissue may have been insufficient to cause a greater reduction in pain, according to Cotler et al., 2015.

Camargo and collaborations (2019) presented that laser protocol of a single application was not effective in reducing pain in women with damaged nipples (660 nm, 100 mW, 2 J, 66.66 J/cm<sup>2</sup>, 3.3 W/cm<sup>2</sup>, 20 s of irradiation, punctual, and continuous mode) applied directly in the center of the largest injury. Women reported pain levels at recruitment (before and immediately after irradiation), 6 and 24 h after the treatment by VAS. Women's perception of pain reduced approximately one point in both groups. Thirty-one percent of participants in the laser group (11/36) reported secondary effects, such as tingling (10/36) and pricking (2/36). In this case, although the authors used a higher dose of energy per point compared to the study by Coca et al., the light caused adverse effects such as a tingling sensation. This probably occurred due an adverse effect of red light in high dose on the melanin-rich tissue, the nipple, a chromophore that absorbs more red light and increase heating. In view of this, our study attempted to deliver a higher dose of energy while avoiding contact with the skin, which is why the prototype was developed. This prototype has a lens that collimates the light beam so that it is evenly distributed in the areola and nipple area, avoiding heating caused by the light on the melanin-rich region, the nipple.

The association of laser with standard treatment has been more efficient, standard treatment proved to be functional and important. Several studies have shown the importance of guidance, positioning, correct latch, and sucking the baby to avoid and/or improve breast injuries. Inadequate latching, for example, may initiate a cascade of negative events that make breastfeeding difficult, including nipple pain and trauma, inefficient milk removal, and inadequate milk production, reasons that can lead to early weaning [32]. Difficulties related to breastfeeding techniques are very common among lactant women, especially those who are breastfeeding for the first time. This is observed in this study, where more than 75% of women reported difficulty in breastfeeding and guidance regarding breastfeeding techniques, breast care and individualized assistance, which involved standard treatment group, was efficient in improving breast lesions.

Therefore, our study showed that the association of the laser

with professional guidance and support with breastfeeding techniques was a positive action to improve nipple trauma and reduce pain in breastfeeding women.

## Conclusion

The present study showed that the use of low-intensity laser with the coupled adapter improved more efficiently the nipple repair, as well as reduced the pain intensity in breastfeeding women. It is believed that the use of low-level laser therapy, by health professionals, contributes to the permanence of exclusive breastfeeding. This new adapter has allowed to expand the irradiated tissue area (nipple and areolar region), facilitating the laser using method, avoiding the accumulation of red light in the melanin present in the nipples, reducing the chance of adverse effects and enabling the use of a higher dose of energy, necessary to promote pain reduction. It is also worth highlighting the importance of guidance regarding breastfeeding techniques and supervision, so that causal factors are reduced to improve these injuries.

## References

- Walker A. Breast Milk as the Gold Standard for Protective Nutrients. *J Pediatr*. 2010; 156(2): 3-7.
- World Health Organization (WHO) WHO recommendations on maternal and newborn care for a positive postnatal experience. 2022.
- Flohr C, Henderson AJ, Kramer MS, Patel R, Thompson J, et al. Effect of an Intervention to Promote Breastfeeding on Asthma, Lung Function, and Atopic Eczema at Age 16 Years: Follow-up of the PROBIT Randomized Trial. *JAMA Pediatr*. 2018; 172(1).
- Smith ER, Hurt L, Chowdhury R, Sinha B, Fawzi W, et al. Delayed breastfeeding initiation and infant survival: A systematic review and meta-analysis. *PLoS One*. 2017; 12(7).
- del Ciampo LA, del Ciampo IRL. Breastfeeding and the Benefits of Lactation for Women's Health. *Rev Bras Ginecol Obstet*. 2018; 40(6): 354-359.
- Unar-Munguía M, Torres-Mejía G, Colchero MA, de Cosío TG. Breastfeeding Mode and Risk of Breast Cancer: A Dose-Response Meta-Analysis. *J Hum Lact*. 2017; 33(2): 422-434.
- Pokhrel S, Quigley MA, Fox-Rushby J, McCormick F, Williams A, et al. Potential economic impacts from improving breastfeeding rates in the UK. *Arch Dis Child*. 2015; 100(4): 334-340.
- Kac G, de Castro IRR, de Aquino Lacerda EM. Brazilian National Survey on Child Nutrition: evidence for food and nutrition policies. *Cad Saude Publica*. 2023; 39(2).
- Morland-Schultz K, Hill PD. Prevention of and therapies for nipple pain: a systematic review. *J Obstet Gynecol Neonatal Nurs*. 2005; 34(4): 428-437.
- Shimoda GT, Soares AVN, Aragaki IMM, McArthur A. Preventing nipple trauma in lactating women in the University Hospital of the University of Sao Paulo: a best practice implementation project. *JB Database System Rev Implement Rep*. 2015; 13(2): 212-232.
- de Abreu Chaves ME, Araújo AR, Santos SF, Pinotti M, Oliveira LS. LED phototherapy improves healing of nipple trauma: a pilot study. *Photomed Laser Surg*. 2012; 30(3): 172-178.
- Cervellini MP, Gamba MA, Coca KP, Abrão ACFDV. Injuries resulted from breastfeeding: a new approach to a known problem. *Rev Esc Enferm USP*. 2014; 48(2): 346-356.
- Buck ML, Amir LH, Cullinane M, Donath SM. Nipple pain, damage, and vasospasm in the first 8 weeks postpartum. *Breastfeed Med*. 2014; 9(2): 56-62.
- Avignon V. Treatment of nipple pain in breastfeeding women in the postpartum ward of the University Hospital of Lausanne: a best practice implementation project. *JB Database System Rev Implement Rep*. 2018; 16(4): 1048-1067.
- Yang L, Wang X, Luo Y, Sun F, Wu M, et al. Management of nipple pain or trauma in breastfeeding mothers in a hospital setting: a best practice implementation project. *JB Evid Implement*. 2021; 19(3): 236-244.
- Anders JJ, Lanzafame RJ, Arany PR. Low-Level Light/Laser Therapy Versus Photobiomodulation Therapy. *Photomed Laser Surg*. 2015; 33(4): 183-184.
- Heiskanen V, Hamblin MR. Correction: Photobiomodulation: lasers vs. light emitting diodes? *Photochem Photobiol Sci*. 2018; 18(1): 259-259.
- Campos TM, Traverzini MADS, Sobral APT, Bussadori SK, Fernandes KSP, et al. Effect of LED therapy for the treatment nipple fissures: Study protocol for a randomized controlled trial *Medicine*. 2018; 97(41).
- Coca KP, Marcacine KO, Gamba MA, Corrêa L, Aranha ACC, et al. Efficacy of Low-Level Laser Therapy in Relieving Nipple Pain in Breastfeeding Women: A Triple-Blind, Randomized, Controlled Trial. *Pain Manag Nurs*. 2016; 17(4): 281-289.
- Breivik H, Borchgrevink PC, Allen SM, Rosseland LA, Romundstad L, et al. Assessment of pain. *Br J Anaesth*. 2008; 101(1): 17-24.
- De Freitas LF, Hamblin MR. Proposed Mechanisms of Photobiomodulation or Low-Level Light Therapy. *IEEE J Sel Top Quantum Electron*. 2016; 22(3): 348-364.
- Chung H, Dai T, Sharma SK, Huang YY, Carroll JD, et al. The nuts and bolts of low-level laser (light) therapy. *Ann Biomed Eng*. 2012; 40(2): 516-533.
- Camargo BTS, Coca KP, Amir LH, Corrêa L, Aranha ACC, et al. The effect of a single irradiation of low-level laser on nipple pain in breastfeeding women: a randomized controlled trial. *Lasers Med Sci*. 2020; 35(1): 63-69.
- Karu T. Mitochondrial mechanisms of photobiomodulation in context of new data about multiple roles of ATP. *Photomed Laser Surg*. 2010; 28(2): 159-160.
- Cirico MOV, Shimoda GT, Silva IA, De Sousa MVP, De Castro R, et al. Effectiveness of photobiomodulation therapy for nipple pain or nipple trauma in lactating women: a systematic review protocol. *JB Evid Synth*. 2021; 19(3): 614-621.
- Glass GE. Photobiomodulation: A review of the molecular evidence for low level light therapy. *J Plast Reconstr Aesthet Surg*. 2021; 74(5): 1050-1060.
- McClellan HL, Geddes DT, Kent JC, Garbin CP, Mitoulas L,

- et al. Infants of mothers with persistent nipple pain exert strong sucking vacuums. *Acta Paediatr.* 2008; 97(9): 1205-1209.
28. Cotler HB, Chow RT, Hamblin MR, Carroll J. The Use of Low Level Laser Therapy (LLLT) For Musculoskeletal Pain. *MOJ Orthop Rheumatol.* 2015; 2(5).
29. Tomazoni SS, Leal-Junior ECP, Pallotta RC, Teixeira S, de Almeida P, et al. Effects of photobiomodulation therapy, pharmacological therapy, and physical exercise as single and/or combined treatment on the inflammatory response induced by experimental osteoarthritis. *Lasers Med Sci.* 2017; 32(1): 101-108.
30. De Almeida P, Tomazoni SS, Frigo L, de Carvalho PDT, Vanin AA, et al. What is the best treatment to decrease pro-inflammatory cytokine release in acute skeletal muscle injury induced by trauma in rats: low-level laser therapy, diclofenac, or cryotherapy? *Lasers Med Sci.* 2014; 29(2): 653-658.
31. Ezzati K, Fekrazad R, Raoufi Z. The Effects of Photobiomodulation Therapy on Post-Surgical Pain. *J Lasers Med Sci.* 2019; 10(2): 79-85.
32. Odom EC, Li R, Scanlon KS, Perrine CG, Grummer-Strawn L. Reasons for Earlier Than Desired Cessation of Breastfeeding. *Pediatrics.* 2013; 131(3): 726-732.