

Cryptocaryon irritans, a ciliate parasite of an ornamental reef fish yellowtail tang *Zebrasoma xanthurum*

Cryptocaryon irritans, parasito ciliado do peixe ornamental de recife “yellowtail tang” *Zebrasoma xanthurum*

Pedro Henrique Magalhães Cardoso^{1*} ; Herbert Sousa Soares¹; Maurício Laterça Martins²; Simone de Carvalho Balian¹

¹ Departamento de Medicina Veterinária Preventiva e Saúde Animal, Faculdade de Medicina Veterinária e Zootecnia, Universidade de São Paulo, São Paulo, SP, Brasil

² Laboratório de Sanidade de Organismos Aquáticos – AQUOS, Departamento de Aquicultura, Universidade Federal de Santa Catarina, Florianópolis, SC, Brasil

Received March 12, 2019

Accepted April 30, 2019

Abstract

Cryptocaryon irritans is an obligate parasitic ciliate protozoan of wild and cultured marine fish. It causes white spot disease, and infections with this pathogen can cause significant losses for aquarists and commercial marine cultures worldwide. This study reports the occurrence of *C. irritans* parasitizing the ornamental reef fish, yellowtail tang, *Zebrasoma xanthurum*. Six days after being introduced to a new environment, 11 yellowtail tangs had white spots scattered across their bodies and fins. Suspicion of infection with *C. irritans* was evaluated by scraping the skin to confirm clinical diagnosis. After confirmation, the yellowtail tangs were transferred to a hospital aquarium and treated with the therapeutic agent Seachem Cupramine® for 15 days. During the treatment period, the copper concentration was monitored daily. At the end of the treatment, none of the yellowtail tangs showed clinical signs of white spots on their bodies, and skin scraping confirmed the yellowtail tangs were no longer infected. Subsequently, the yellowtail tangs were released for sale.

Keywords: Imported ornamental fish, aquatic health, parasitic disease, seachem Cupramine®, Treatment.

Resumo

Cryptocaryon irritans é um protozoário ciliado parasita obrigatório de peixes marinhos selvagens e cultivados. Causa a doença dos “pontos brancos”. Infecções por esse patógeno pode causar perdas significativas para aquaristas e para marinocultura comercial em todo o mundo. Este estudo relata a ocorrência de *C. irritans* parasitando a espécie de peixe ornamental de recife *Zebrasoma xanthurum*. Seis dias após serem introduzidos no novo ambiente, onze peixes apresentaram pontos brancos espalhados pelo corpo e nadadeiras. Suspeitando de infecção por *C. irritans* foi realizado raspado de pele para confirmar o diagnóstico clínico. Após a confirmação, os peixes foram transferidos para um aquário hospital e tratados com o agente terapêutico Seachem Cupramine® por 15 dias. Durante o período de tratamento o monitoramento da concentração de cobre foi diário através da utilização de um fotômetro. Após o final do tratamento, todos os peixes já não apresentavam mais sinais clínicos de pontos brancos pelo corpo, e foram negativos no raspado de pele, sendo encaminhados para comercialização.

Palavras-chave: Peixe ornamental importado, saúde aquática, doença parasitária, Seachem Cupramine®, tratamento.

The ornamental fish trade is characterized by the aggregation of fish species from several countries. More than 1,450 marine fish species are commercialized as ornamental fish, and approximately 90% of these are wild-caught. There are many pathogenic agents, including metazoans, protozoans, bacteria, and viruses, which may be transferred together with the translocated fish, and this may lead to disease outbreaks (WHITTINGTON & CHONG, 2007).

Zebrasoma xanthurum, known as the purple tang or yellowtail tang, is a species of reef surgeonfish in the family Acanthuridae. It was first described by zoologist Edward Blyth in 1852. Yellowtail tangs have been found in the Gulf of Aden, the Persian Gulf, and the Arabian Sea, and are frequently exported to Brazil as ornamental reef fish. Yellowtail tangs typically inhabit coral reef ecosystems, where they are found eating filamentous algae present in the reef (FROSE & PAULY, 2019).

Cryptocaryon irritans Brown, 1951 (Prostomatea) is a ciliate protozoan parasite of wild and cultured marine fish, and causes white spot disease. It results in significant losses for aquarists and commercial fishermen worldwide by infecting a wide variety of

*Corresponding author: Pedro Henrique Magalhães Cardoso.

Departamento de Medicina Veterinária Preventiva e Saúde Animal, Faculdade de Medicina Veterinária e Zootecnia, Universidade de São Paulo, Rua Professor Orlando Marques Paiva, CEP 05508270, São Paulo, SP, Brasil. e-mail: pedrohenriquemedvet@usp.br



marine fish, although some species are more susceptible than others (LIPTON, 1993; CHI et al., 2017; MO et al., 2017; JIANG et al., 2018; VAN & NHINH, 2018; YIN et al., 2018).

Fish infected with *Cryptocaryon* spp. have white spots or nodules on their fins, skin, and/or gills. They may also have pale gills, increased mucus production, or changes in skin color, irritation, and weight loss (COLORNI & BURGESS, 1997; NOGA, 2010). Because white spots or nodules are not easy to see on light-colored fish, the observation of the absence of nodules or white spots with the naked eye does not rule out *Cryptocaryon* spp. infection, hence the importance of diagnostic testing. If fish are infected with *Cryptocaryon* spp., mortality may increase rapidly over the course of days. However, the extent of the disease will depend on the virulence of the isolate, previous exposure to the parasite, and water temperature (YANONG, 2009).

Experiments by Colorni (1987) at temperatures of 24–25°C showed that the life cycle of *C. irritans* varied from eight to 10 days. This is similar to the findings of Dan et al. (2006) who observed that, at $27.0 \pm 0.5^\circ\text{C}$, the parasite could complete its life cycle in just seven days. However, the time taken to complete the life cycle can vary between days and months, depending on the water temperature and the host species (YANONG, 2009). The most common stage found is the trophont (feeding stage), which is found in the layer below the host's skin, where it is protected against most therapeutic agents. This stage typically lasts between three and seven days. When the trophont leaves the fish, it becomes a protomont, before encysting and turning into a tomont (reproductive stage). The tomont develops and divides into numerous tomites, which eventually leave the cyst as theronts, the infective and free-swimming stages. Theronts actively seek host fish, and it is at this stage that most therapeutic agents can act (YANONG, 2009). If the disease is not treated early, the mortality rate may reach 100% in a few days (COLORNI & BURGESS, 1997). The most commonly used treatments are prolonged continuous baths based on copper (NOGA, 2010; YANONG, 2009).

This study aimed to identify the White spot disease caused by *C. irritans* in yellowtail tang *Z. xanthurum* and to report efficacious treatment with the commercial product Seachem Cupramine® that according to the manufacturer is non acidic, nontoxic for fish and does not contaminate the filter being removable with carbon.

Yellowtail tangs ($n = 22$), weighing approximately 65.0 ± 5.0 g and 8.5 ± 2.0 cm long were obtained from a wholesale retailer after they were imported to São Paulo, southeastern Brazil, and quarantined (BRASIL, 2015). The yellowtail tangs were originally captured in August 2018 from their natural habitat in the Red Sea, an inlet of the Indian Ocean, and were bought from an exporter in Djibouti ($11^\circ35'20''$ N; $43^\circ8'42''$ E).

The yellowtail tangs were maintained in reef aquaria with a recirculation system of 3.4 m^3 , and fed three times a day with a commercial diet (Germany, Tetra® Marine flakes and granules) until the apparent satiety. Water quality parameters were measured daily and maintained at the following settings: temperature of 26°C , salinity of 29 g L^{-1} , dissolved oxygen content of 5 mg L^{-1} , alkalinity of 9 dKH, pH of 8.2, and a total ammonia concentration of $<0.1\text{ mg L}^{-1}$. Yellowtail tangs were released in the reef aquarium with no apparent clinical signs, but six days after arriving, the retailer's veterinary technician observed that 13 yellowtail tangs exhibited behavioral changes, such as flashing, as well as having white spots on their bodies and fins (Figure 1A-B). Suspecting *Cryptocaryon* sp. infection, three yellowtail tangs were subjected to skin scraping to confirm diagnosis by microscopic identification.

Subsequently, the yellowtail tangs were transferred to a hospital aquarium of 0.6 m^3 with the same water quality parameters as described above, and no activated carbon. In the aquarium, yellowtail tangs were treated for 15 days, with 15 mL of Seachem Cupramine® ($10,000\text{ mg L}^{-1}$) added on the first day (day 1), and 7 mL of Seachem Cupramine® added after 48 h (day 3) (NOGA, 2010). The copper concentration was measured daily with LaMotte DC1500 COPPER tests. No water changes was observed during the treatment. Temperature was controlled by thermostats. The water from the bottom of the aquaria was siphoned two times a day and




Figure 1. A-B: Yellowtail tang *Zebrasoma xanthurum* with white spots in the body and fins.

new salt water with the same salinity added. After 15 days, the treatment was completed, and 300 g of activated charcoal Hw[®] was used to remove the copper residues added. During treatment in the hospital, the yellowtail tangs were fed five times a day with a commercial diet (Germany Tetra[®] Marine flakes and granules) and chard until the apparent satiety.

The ciliate protozoans present on the body surface and fins of yellowtail tangs was identified as *Cryptocaryon irritans* (Figure 2). On the third day after addition of Seachem Cupramine[®], the concentration of copper in the water was 0.24 mg L⁻¹ and on the 15th day it was 0.16 mg L⁻¹ (Table 1). All the treated yellowtail tangs that had previously had white spots on their bodies did not have parasites that were visible to the naked eye seven days after beginning treatment, and the parasite was not observed in skin scrapings. However, the yellowtail tangs were kept in the hospital aquarium and treated with the medication until the 15th day, after which the yellowtail tangs were released for sale.

The studies of Van & Ninh (2018) showed that the prevalence of *C. irritans* vary widely with the fish host and captured seasons. Some species like *Chaetodon adiergastos*, *Paracanthurus hepatus*, *Amphiprion frenatus*, *Diodon holocanthus*, *Platax teira* sp., *Pterois volitans*, *Plectorhinchus vittatus*, *Siganus guttatus* and *Pygoplites diacanthus* are very susceptible to the parasite infection (up to 70%) while others like *Rhinecanthus aculeatus*, *Zebrasoma veliferum* and *Zanclus cornutus* are infected at a much lower rate (less than 50% infected). These findings provide important information which can be employed by aquarists in keeping and treating this parasite for ornamental fish in a confined condition.

Fish infected with *C. irritans* need rapid diagnosis because of the high mortality rate in a few days (COLORNI & BURGESS, 1997; NOGA, 2010). Light-colored species such as yellow tangs *Zebrasoma flavescens*, commonly die due to a lack of early diagnosis, which is due to the difficulty in visualizing white spots by untrained professionals (P.H.M Cardoso, personal observation).

The early diagnosis of fish infected with *C. irritans* and the adoption of therapeutic measures with therapeutic chemicals based on copper sulfate improve the clinical signs of the disease (YANONG, 2009). The commercial product Seachem Cupramine[®] used in this study improved the prognosis of the disease in yellowtail tangs. It is important that, immediately upon suspicion of infection with *C. irritans*, the owner of the fish should seek the assistance of a trained professional to correctly identify the disease and apply the appropriate treatment as soon as possible, as the mortality rate may reach 100% if the disease is not treated, which can cause great harm to ornamental fish stores.

Therapeutic agents act on the theronts, which are infective for up to 24 to 48 h after encystment at temperatures of 24 to 27°C. The recommended minimum dose of therapeutic agents is 0.15 to 0.20 mg L⁻¹ for 14 to 21 days to eliminate theronts. In the present study, the initial dose after 48 h was 0.24 mg L⁻¹, and the dosage was reduced to 0.16 mg L⁻¹ on the 15th day of the treatment. The dose of 0.24 mg L⁻¹ was not toxic to yellowtail tangs, but, according to the literature, doses of 0.5 to 1 mg L⁻¹ are toxic to most marine fish species (COLORNI, 1987). The treatment of some marine fish such as two-spined angelfish *Centropyge bispinosa*, flame angel *Centropyge loricula*, Indian sailfin tang *Zebrasoma desjardinii*, brushtail tang *Zebrasoma scopas*, *Zebrasoma veliferum* and yellow boxfish *Ostracion cubicus* with therapeutic agents based on copper sulfate should be applied with caution. Our experience indicates that such species are sensitive to doses above 0.3 mg L⁻¹ (P. H. M. Cardoso, personal observation). Therefore, the use of the therapeutic agent should be monitored for each species to be treated.

Ornamental imported fish fetch high commercial price in the National Market once they are bought in dollars. However, the import and international transportation of these fish is costly, which increases the costs of each batch of fish. In order to minimize the economic losses and mortality due to parasitic diseases, and to

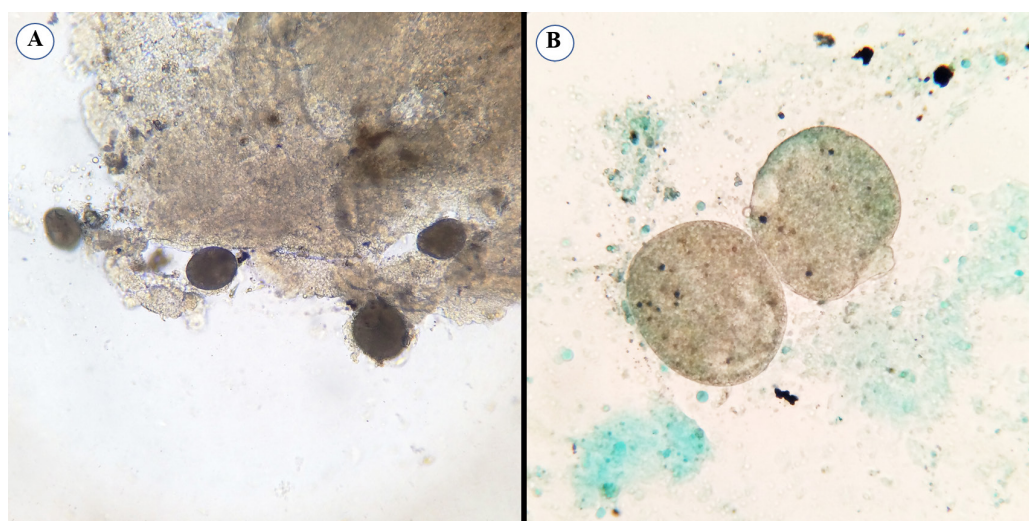


Figure 2. Ciliated parasite *Cryptocaryon irritans* microscopic magnification A:10 x and B: 20 x.

Table 1. Dose concentration of copper used during 15 days in treatment of *Zebrasoma xanthurum*.

Day	1	2	3	4	5	6	7	8	9	10	11	12	13	14	15
Copper concentration (mg/L)	0.24	0.24	0.23	0.23	0.23	0.22	0.22	0.21	0.19	0.19	0.18	0.18	0.18	0.17	0.16

promote fish welfare, it is necessary to take care of the fish until they are sold (CARDOSO et al., 2017, 2019).

In this report, white spot disease was detected early in yellowtail tangs, and the efficacy of the Seachem Cupramine® treatment was demonstrated, which avoided losses of fish due to mortality. These results emphasize the importance of the correct diagnoses and the early treatment to avoid losses. In addition to the rapid treatment to kill theronts, the empty sanitary needed to disinfect the system avoids stages of trophont and tomont that may remain dormant for months.

Acknowledgements

We thank National Council of Scientific and Technological Development (CNPq) for research grant to M.L. Martins (CNPq # 306635/2018-6), for Sabbatical fellowship to P.H.M. Cardoso (CAPES 1808006), and William E. Furtado (AQUOS, UFSC) for parasite pictures. This study was financed in part by the Coordenação de Aperfeiçoamento de Pessoal de Nível Superior - Brasil (CAPES) - Finance Code 001.

References

- Brasil. Ministério da Pesca e Aquicultura. Instrução Normativa no 4, de 4 de fevereiro de 2015. *Diário Oficial [Da] União*, Brasília, 09 fev. 2015.
- Cardoso PHM, Balian SC, Matushima ER, Pádua SB, Martins ML. First report of scuticociliatosis caused by *Uronema* sp. in ornamental reef fish imported into Brazil. *Rev Bras Parasitol Vet* 2017; 26(4): 491-495. <http://dx.doi.org/10.1590/s1984-29612017031>. PMID:28658416.
- Cardoso PHM, Balian SC, Soares HS, Tancredo KR, Martins ML. *Neobenedenia melleni* (Monogenea: Capsalidae) in ornamental reef fish imported to Brazil. *Rev Bras Parasitol Vet* 2019; 28(1): 157-160. <http://dx.doi.org/10.1590/s1984-296120180076>. PMID:30540114.
- Chi H, Taik P, Foley EJ, Racicot AC, Gray HM, Guzzetta KE, et al. High genetic diversities between isolates of the fish parasite *Cryptocaryon irritans* (Ciliophora) suggest multiple cryptic species. *Mol Phylogenet Evol* 2017; 112: 47-52. <http://dx.doi.org/10.1016/j.ympev.2017.04.015>. PMID:28428147.
- Colorni A, Burgess P. *Cryptocaryon irritans* Brown 1951, the cause of 'white spot disease' in marine fish: an update. *Aquarium Sci Conserv* 1997; 1(4): 217-238. <http://dx.doi.org/10.1023/A:1018360323287>.
- Colorni A. Biology of *Cryptocaryon irritans* and strategies for its control. *Aquaculture* 1987; 67(1-2): 236-237. [http://dx.doi.org/10.1016/0044-8486\(87\)90041-X](http://dx.doi.org/10.1016/0044-8486(87)90041-X).
- Dan XM, Li AX, Lin XT, Teng N, Zhu XQ. A standardized method to propagate *Cryptocaryon irritans* on a susceptible host pompano *Trachinotus ovatus*. *Aquaculture* 2006; 258(1-4): 127-133. <http://dx.doi.org/10.1016/j.aquaculture.2006.04.026>.
- Froese R, Pauly D. *Editors fish base* [online]. 2019 [cited 2019 Apr 1]. Available from: <https://www.fishbase.se/summary/12023>
- Jiang B, Li Y, Li A. The development of *Cryptocaryon irritans* in a less susceptible host rabbitfish, *Siganus oramin*. *Parasitol Res* 2018; 117(12): 3835-3842. <http://dx.doi.org/10.1007/s00436-018-6088-z>. PMID:30238188.
- Lipton AP. *Cryptocaryon irritans* (Protozoa: Ciliata) infection among aquarium-held marine ornamental fish and its control. *Curr Sci* 1993; 65(7): 571-572.
- Mo ZQ, Wang J, Yang M, Ni L, Wang H, Lao GF, et al. Characterization and expression analysis of grouper (*Epinephelus coioides*) co-stimulatory molecules CD83 and CD80/86 post *Cryptocaryon irritans* infection. *Fish Shellfish Immunol* 2017; 67: 467-474. <http://dx.doi.org/10.1016/j.fsi.2017.05.064>. PMID:28579524.
- Noga EJ. *Fish disease: diagnosis and treatment*. 2nd. Ames: Willey; 2010.
- Van KV, Ninh DT. The prevalence of *Cryptocaryon irritans* in wild marine ornamental fish from Vietnam. *IOP Conf Ser Earth Environ Sci* 2018; 137: 012094. <http://dx.doi.org/10.1088/1755-1315/137/1/012094>.
- Whittington RJ, Chong R. Global trade in ornamental fish from an Australian perspective: the case for revised import risk analysis and management strategies. *Prev Vet Med* 2007; 81(1-3): 92-116. <http://dx.doi.org/10.1016/j.prevetmed.2007.04.007>. PMID:17485126.
- Yanong RPE. *Cryptocaryon irritans* infections (Marine White Spot Disease) in Fish. *IFAS Ext. University Florida* 2009; FA164: 1-9.
- Yin F, Liu W, Bao P, Jin S, Qian D, Wang J, et al. Comparison of the susceptibility and resistance of four marine perciform fishes to *Cryptocaryon irritans* infection. *Fish Shellfish Immunol* 2018; 77: 298-303. <http://dx.doi.org/10.1016/j.fsi.2018.03.052>. PMID:29605505.